


Biodegradable polyurethane meniscal scaffold for isolated partial lesions or as combined procedure for knees with multiple comorbidities: clinical results at 2 years

Elizaveta Kon, Giuseppe Filardo, Stefano Zaffagnini, Alessandro Di Martino, Berardo Di Matteo, Giulio Maria Marcheggiani Muccioli, et al.

**Knee Surgery, Sports Traumatology,
Arthroscopy**

ISSN 0942-2056

Knee Surg Sports Traumatol Arthrosc
DOI 10.1007/s00167-012-2328-4



Your article is protected by copyright and all rights are held exclusively by Springer-Verlag Berlin Heidelberg. This e-offprint is for personal use only and shall not be self-archived in electronic repositories. If you wish to self-archive your work, please use the accepted author's version for posting to your own website or your institution's repository. You may further deposit the accepted author's version on a funder's repository at a funder's request, provided it is not made publicly available until 12 months after publication.

Biodegradable polyurethane meniscal scaffold for isolated partial lesions or as combined procedure for knees with multiple comorbidities: clinical results at 2 years

Elizaveta Kon · Giuseppe Filardo · Stefano Zaffagnini · Alessandro Di Martino ·
Berardo Di Matteo · Giulio Maria Marcheggiani Muccioli ·
Maurizio Busacca · Maurilio Marcacci

Received: 11 September 2012 / Accepted: 26 November 2012
© Springer-Verlag Berlin Heidelberg 2012

Abstract

Purpose The aim of this study is to evaluate the safety and clinical efficacy of this novel polyurethane meniscal scaffold to treat partial meniscal loss.

Methods Eighteen patients (11 men and 7 women, mean age: 45 years) affected by irreparable acute meniscal tears requiring partial meniscectomy or chronic prior loss of meniscal tissue were enrolled in the study. They underwent arthroscopic polyurethane meniscal scaffold implantation (13 medial and 5 lateral) and, in case of presence of other comorbidities, concurrent procedures were also performed. Patients were prospectively evaluated up to 2 years of follow-up through IKDC objective, IKDC subjective, and Tegner scores. Furthermore, MRI evaluation of the meniscal scaffold was performed.

Results No major adverse events were observed. A statistically significant increase in all the clinical parameters considered was found. The IKDC objective score increased from 61 % of normal or nearly normal knees at basal evaluation to 94 % at 2 years of follow-up ($p = 0.01$). There was also a significant increase in the IKDC subjective score both at 6–12 months of follow-up ($p = 0.03$

and $p < 0.005$), which was confirmed at 24 months. The Tegner score also showed a significant increase from the pre-operative level (median value 2, range 1–5) to final evaluation (median value 3, range 2–5; $p = 0.005$), albeit not reaching the pre-injury sports activity level.

Conclusions The implantation of this novel polyurethane scaffold proved to be a safe and potentially effective procedure to treat partial meniscal loss with encouraging results at short-term follow-up. Further high-quality studies with larger numbers of patients and longer evaluation times are needed to confirm these preliminary data.

Level of evidence Case series, Level IV.

Keywords Meniscectomy · Polyurethane meniscal scaffold · Regenerative medicine · Prospective evaluation

Introduction

Menisci have been found to play a vital role in the maintenance of knee homeostasis. They allow articular congruency and stability, besides load distribution and shock absorption, and provide lubrication and proprioception, too [22]. Any substantial loss of meniscal tissue from injury or iatrogenic meniscectomy can alter permanently the biomechanical and biological environment of the joint [16]. Subtotal or total meniscectomy can increase the risk of secondary osteoarthritic changes resulting in radiographic changes in 30–70 % of patients, and biomechanical studies have shown significant alteration in load transmission also in cases of smaller meniscal deficiency or mismatch [10, 12]. Unfortunately, lesions of the meniscus are frequently observed in orthopaedic practice, with a mean annual incidence of 60–70 per 100,000 [33]. Damage or loss of meniscal tissue leads to pain and knee dysfunction,

E. Kon (✉) · G. Filardo
Nano-Biotechnology Laboratory, Rizzoli Orthopaedic Institute,
Via di Barbiano n. 1/10, 40136 Bologna, Italy
e-mail: e.kon@biomec.ior.it

S. Zaffagnini · A. Di Martino · B. Di Matteo ·
G. M. Marcheggiani Muccioli · M. Marcacci
Biomechanics Laboratory and III Orthopaedic Clinic,
Rizzoli Orthopaedic Institute, Via di Barbiano n. 1/10,
40136 Bologna, Italy

M. Busacca
Department of Radiology, Rizzoli Orthopaedic Institute,
Via di Barbiano n. 1/10, 40136 Bologna, Italy

making a meniscectomy often inevitable despite its well-known deleterious effects [4, 7, 35].

The possibility of preserving or reconstructing the meniscal structure should be always considered, especially in young active patients, and even more so in symptomatic cases following meniscal loss. Biomechanical studies have shown an improved contact area and peak stresses with meniscal transplantation and even though degenerative changes were not completely avoided, they were reduced in comparison with meniscectomized controls [1, 2, 19, 26, 32]. Therefore, in order to replace the damaged meniscus, many solutions have been studied, ranging from artificial materials, autogenous tissue, and allograft tissue [15, 24]. Among these, two options are now available in clinical practice for meniscal substitution: allograft transplantation and collagen meniscus implant (CMI) [9]. In particular, these surgical treatments have different indications. In fact, whereas meniscus allografts are indicated when it is necessary to restore all or nearly all the injured meniscus, with good results reported at long-term follow-up [21, 31, 34], scaffold-based repair is suitable to fill meniscus defects after a partial meniscectomy, since it requires a meniscal rim for attachment [9]. Several studies have shown safety and good early- to mid-term clinical results using a CMI (Menaflex[®], ReGen Biologics, Inc., Franklin Lakes, NJ, USA) [6, 24, 31, 38]. However, difficulties in tissue handling with respect to suturing during implantation have highlighted the need for newer improved materials for scaffolds [6]. Recently, a novel polyurethane scaffold has been introduced into clinical practice (Actifit[®], Orteq Sports Medicine, London, UK). Polyurethanes are believed to have better material properties to suture to the remaining tissue and to resist the extreme forces within the knee joint [5].

The implantation of this novel meniscal scaffold was hypothesized to be a safe procedure capable of determining clinical improvement at short-term follow-up in patients affected by partial meniscal loss.

Materials and methods

In this clinical trial, 18 consecutive patients were enrolled, treated, and prospectively evaluated. The patients were 11 men and 7 women, with a mean age of 45 years (s.d.: 12.9). The inclusion criteria of the study were: irreparable acute meniscal tears requiring partial meniscectomy or chronic prior loss of meniscal tissue (traumatic or degenerative) greater than 25 %, intact anterior and posterior attachments of the meniscus, intact rim (1 mm or greater, evaluated during the arthroscopy) over the entire circumference of the involved meniscus, skeletally mature male or female patients. The exclusion criteria were: non-corrected axial deviation or knee instability (axial deviation and knee

instability were evaluated clinically and via X-ray examination). The patients who presented with an ACL lesion at the time of surgery underwent the combined surgical procedure of ACL reconstruction in the same surgical session. Analogously, patients presenting axial deviation underwent an osteotomy treatment for limb realignment in the same surgical session. Patients with documented allergy to scaffold components, history of anaphylactoid reaction, systemic administration of any type of corticosteroid or immunosuppressive agents within 30 days of surgery, evidence of osteonecrosis in the involved knee and history of infectious, neoplastic, metabolic, and inflammatory pathologies were also excluded from the study. All patients gave informed consent, and the study was approved by the local ethics board.

The sites of the defects were 13 medial and 5 lateral menisci. Only one patient was treated for the first time, whereas 17 patients had undergone previous surgeries: 16 meniscectomies, 6 ACL reconstructions, 2 osteotomies, 2 shavings, 1 microfracturing, 1 re-fixation of an osteochondral fragment, and 1 patellar realignment. In 11 patients, other combined procedures were performed during the same operation: 4 osteotomies, 3 ACL reconstructions, 2 lateral releases, 1 loose body removal, and 7 treatments of articular surface lesions (3 microfractures, 2 osteochondral scaffold implants, 1 chondroabrasion, and 1 shaving).

Surgical procedure and postoperative treatment

The surgical procedure of scaffold implantation was performed through an arthroscopic approach. After preparing the implant site and making a full-thickness meniscus defect without degenerative tissue, the anterior and posterior meniscal attachment points were trimmed square for the scaffold to fit in precisely. After measuring the prepared meniscus defect, the polyurethane scaffold Actifit[®] was trimmed to fill the defect. The implant was inserted into the defect and secured to the host meniscus remnant with all-inside sutures (non-absorbable ULTRABRAID No. 0 wire and poly-L-lactide bioabsorbable ULTRA FAST-FIX implants, Smith & Nephew, Andover, Massachusetts). Vertical/oblique stitches were placed every 5 mm, while horizontal stitches were used only in the posterior and anterior junctions. All the surgical procedures were performed by the senior surgeons of the same surgical equipe.

After the operation, a knee brace was immediately applied and locked in full extension. The brace was continuously worn by the patient for 4 weeks, but it was removed 4 times daily to allow continuous passive motion (CPM): CPM from 0° to 60° was allowed for the first 2 weeks, then increased to 90° of flexion and after another

2 weeks complete passive motion was allowed. Weight bearing was not allowed for the first 2 weeks and ambulation was permitted only using crutches. Then, progressive weight bearing was allowed towards full weight bearing. Early isometric exercises were performed. Voluntary muscular contraction and neuromuscular electrical stimulation (NMES) were indicated and could be started at patient discharge. Elastic resistance and isotonic strengthening programs were started in the fourth postoperative week. Rehabilitation protocol was peculiarly adapted to the patients according to concurrent procedures and postoperative clinical trend.

Patients were allowed to return to full unrestricted activity as tolerated after 6 months if asymptomatic and with regained neuromuscular control. For contact sports, return to full activity was usually allowed after 9 months [38].

Patient evaluation

The clinical outcome of all patients was analysed using the Cartilage Standard Evaluation Form as proposed by the International Cartilage Repair Society (ICRS) [11]. In particular, the IKDC objective and subjective scores have been applied. For what concern the former score, a knee functional test was performed according to the IKDC Knee Examination Form: the lowest ratings in effusion, passive motion deficit, and ligament examination were used to determine the final functional grade of the knee (A = normal, B = nearly normal, C = abnormal, or D = severely abnormal) [11]. Returning to sport was also evaluated with the Tegner score and compared with pre-operative and pre-injury levels. Eighteen patients were prospectively evaluated before the operation and at 6, 12, and 24 months of follow-up. One patient sustained a reinjury during the second year of follow-up while practicing sport activity, thus this score could not be considered for the final evaluation.

Sixteen patients also underwent MRI evaluation between 1 and 2 years of follow-up (one was unavailable and another one presented marked artifacts), and were analysed for morphology, signal intensity, and interface of the implant-residual meniscus complex as previously described in the literature [8]. The first two characteristics were classified from 1 to 3: a higher score corresponded to characteristics similar to those of normal meniscal tissue, the third one was classified as present or absent.

Statistical analysis

All continuous data were expressed in terms of the mean and the standard deviation of the mean. The Mann–Whitney test evaluated by the Exact method for small samples

was performed to assess differences between groups. The paired *T* test with Bonferroni's correction for multiple comparisons was performed to test differences of the continuous scores at different follow-up times. The Wilcoxon test with Bonferroni's correction for multiple comparison was used to test differences among different follow-up times of ordinal scores. Pearson's correlation was used to assess the correlation between continuous variables. For all tests, $p < 0.05$ was considered significant.

Statistical analysis was carried out by using the statistical package for the Social Sciences (SPSS) software version 15.0 (SPSS Inc., Chicago, USA).

Results

No major adverse events were reported during follow-up evaluation.

A statistically significant improvement of all clinical scores was obtained from basal evaluation to the follow-up visits. The IKDC objective score changed from 61.1 % normal (grade A) and nearly normal (grade B) knees before the treatment (7A, 4B, 2C, and 5D) to 77.8 % normal and nearly normal knees (6A, 8B, 2C, and 2D) at the 6-month follow-up (n.s.) and 83.3 % (11A, 4B, 2C, and 1D) and 94.1 % (11A, 5B, and 1D) normal and nearly normal knees at 12 and 24 months of follow-up, respectively, showing a statistically significant improvement with respect to the baseline level ($p = 0.02$ at 12 months, $p = 0.01$ at 24 months). The IKDC subjective score improved markedly from the baseline evaluation to the 6-month follow-up (from 47.3 ± 17.5 to 58.5 ± 16.0 , $p = 0.03$), and a further improvement was found at 12 months ($p < 0.0005$) and maintained at the 24-month follow-up (72.9 ± 13.9 and 74.6 ± 15.3 , respectively) (Fig. 1).

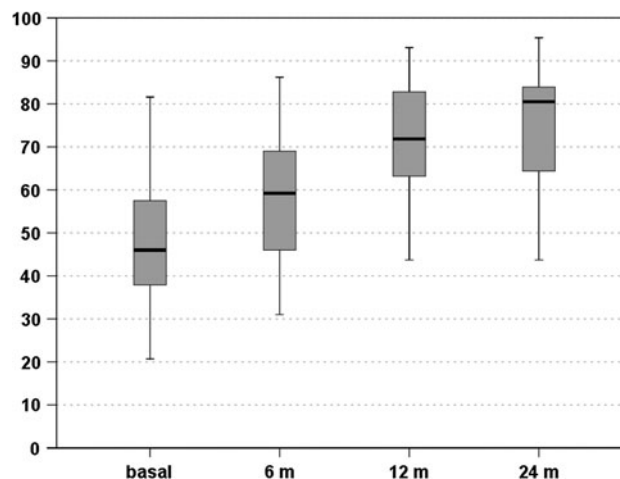


Fig. 1 IKDC subjective score: improvement from the pre-operative level to 6, 12, and 24 months of follow-up

The median Tegner score was 6 (range 3–8) pre-injury, 2 (range 1–5) pre-operatively, 3 (range 1–5) at 6 months, 4 (range 2–5) at the 12-month follow-up, and 3 (range 2–5) after 2 years. These results showed a statistically significant improvement from the pre-operative level to the 1- and 2-year follow-ups ($p = 0.004$ and $p = 0.005$, respectively), and the results remained stable over time; however, the new level of sport activity was significantly lower with respect to the pre-injury level ($p = 0.009$ at 24 months) (Fig. 2).

Further analysis was performed to determine the parameters that influenced the clinical outcome.

Patients who underwent combined surgery, such as cartilage treatment and osteotomy, presented a slower improvement, with lower IKDC subjective scores at 1 year (67.7 ± 15.1 vs. 78.0 ± 11.1 , $p = 0.01$), but achieving similar results after 2 years (71.1 ± 15.0 and 77.7 ± 15.7 with or without combined surgery, respectively) (Fig. 3).

Other factors, such as age, sex, BMI, site (medial or lateral), previous surgery, and aetiology did not influence the results obtained at the different follow-ups in our series.

Sixteen patients were evaluated with high resolution MRI (Fig. 4) for morphology, signal intensity, and interface of the implant-residual meniscus complex: morphology was type 3 in 4 cases, type 2 in 6 cases, and type 1 in 6 cases; signal intensity was type 2 in 10 cases and type 1 in 6 cases; an interface between the implant and the native meniscus could be identified in 6 patients.

Discussion

The most important finding of the present study is that the implantation of the polyurethane meniscal scaffold provides interesting clinical outcome at short-term evaluation, both in case of isolated partial meniscal lesions and as a combined surgical procedure when treating knees affected by multiple comorbidities. The two-year follow-up of this

pilot clinical study showed an improvement in all the parameters evaluated. The objective evaluation showed an improvement at 6 months of follow-up that remained stable over time. The subjective evaluation presented an improvement at 6 months that further increased at the 12- and 24-month follow-ups. The mean Tegner score improved from the pre-operative level to 12 months of follow-up and remained stable up to 24 months, even if significantly lower with respect to the pre-injury level. Different trends in the clinical outcome were seen; in fact, combined surgery was found to be responsible for the delay in functional recovery: patients who underwent combined surgery, such as cartilage treatment and osteotomy, presented a slower improvement, with lower IKDC subjective scores at 1 year, but achieved similar results after 2 years.

Finally, good results were also found with the MRI evaluation with regard to implant morphology, even if the signal was still hyper-intense in all scaffolds between 1 and 2 years of follow-up.

For practical and ethical reasons, we did not perform a histological study. However, the clinical and MRI evaluations showed good results, confirming that this polyurethane meniscal scaffold may be successfully applied in the treatment of partial meniscal loss. In the last years, tissue engineering and regenerative medicine strategies have been constantly applied in the field of meniscal pathology [20]. Satisfactory results were reported with the use of a collagen-based meniscal scaffold. Back in 1997, Steadman and Rodkey published a preliminary clinical trial consisting of 10 patients treated with CMI implantation and evaluated up to 36 months [11]. Clinical outcome was encouraging and patients' satisfaction pretty high in terms of function recovery. The same authors reported longer-term results in 8 male patients treated with medial CMI and evaluated up to mean 5.8 years of follow-up [24]. Lysholm and Tegner scores were statistically significant at final evaluation and radiographs revealed neither degeneration in the medial compartment nor change in the knee mechanical axis with respect to previous follow-ups. A bigger multicentric study led by the same authors and involving a total of 311 patients was published in 2008 [21]. Clinical results at a mean 5 years of follow-up were positive: even if in the acute group no difference was observed between patients treated with CMI and meniscectomy, in the "chronic group" patients showed significantly higher sports activity level and lower re-operation rate with respect to controls. Zaffagnini et al. published [36] the encouraging clinical results of 8 patients treated with CMI implantation, at a mean of 6.8 years' follow-up. The same group published a prospective trial [38] comparing the long-term results of partial medial meniscectomy vs. medial CMI implantation. Thirty-three patients (17 in the scaffold group and 16 in the meniscectomy group) were evaluated at a minimum of

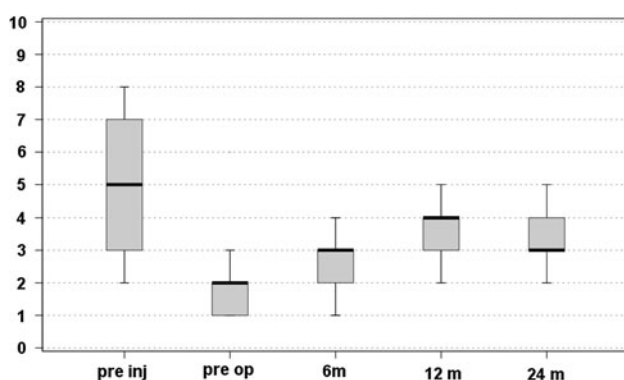


Fig. 2 Comparison of Tegner scores before the injury, before treatment and at 6, 12, and 24 months of follow-up

Fig. 3 IKDC subjective score: patients who underwent combined surgery presented a slower recovery but reached similar good results at the 2-year follow-up evaluation

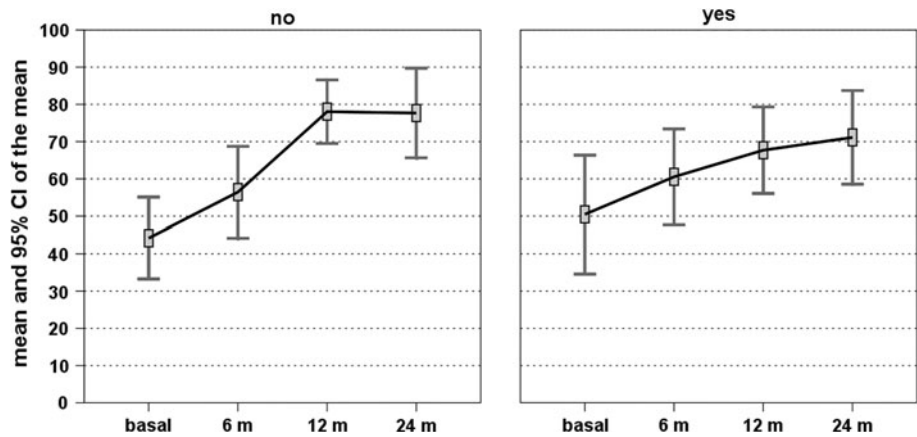
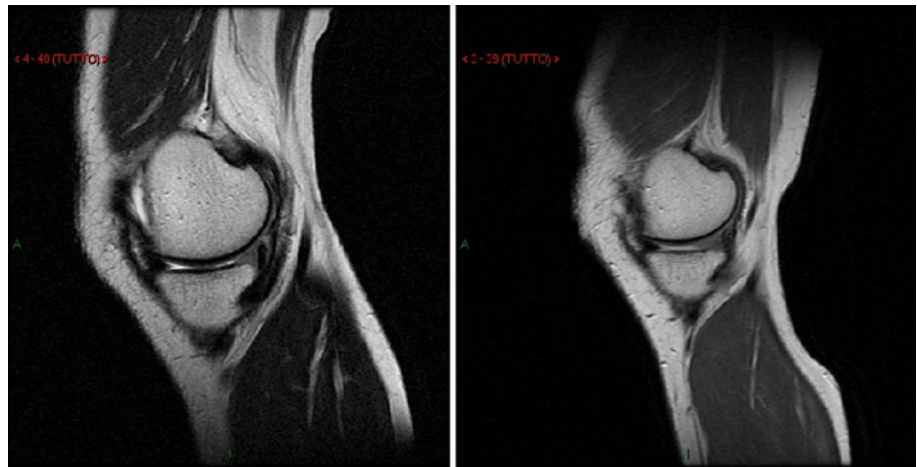


Fig. 4 MRI evaluation of a medial polyurethane meniscal scaffold at 12 months (*left*) and 24 months (*right*) of follow-up



10 years' follow-up: significantly lower VAS for pain and higher objective IKDC, Tegner, and SF-36 were recorded in patients treated with CMI. MRI evaluation showed stable appearance of the scaffold between 5- and 10-year follow-ups. A case report was also published by Zaffagnini and colleagues, concerning a 24-year-old professional athlete treated with lateral CMI implant, who was able to get back to previous sports activity level and maintain his physical performance up to 3 years after surgery [37].

Other studies at mid- and long-term follow-up have been published by Bulgheroni and Monllau [3, 18]: good and stable clinical outcome was reported in both studies and the high level of patient satisfaction, low failure rate, and the absence of device-related complications further reinforced the safety and efficacy of this particular device.

Recently, a novel meniscal implant, Actifit[®], has been developed: it is a biodegradable, synthetic, acellular scaffold composed of aliphatic polyurethane, designed to treat symptomatic segmental defects of both medial and lateral menisci in order to re-establish their biomechanical function. Promising preclinical studies [13, 14, 17, 27, 28] were performed and they showed that the highly porous structure was able to allow biological ingrowth of fibro-vascular

tissue without stimulating foreign body reaction. Mid-term evaluation 24 months after implantation in a dog model [27] revealed that the polyurethane scaffold had still not degraded, thus showing a slow process of differentiation into typical meniscus-like tissue.

In the light of these encouraging pre-clinical studies, this scaffold has been introduced into clinical practice with promising results.

The first article was published by Verdonk et al. In 2011 [30], they studied tissue ingrowth in 52 patients (mean age: 30.9 years). Patients were studied via dynamic contrast-enhanced MRI performed after 3 months to assess tissue ingrowth and via standard MRI at 1 week, 3 and 12 months after surgery to check for any change in articular cartilage. At 12 months, second-look arthroscopy combined with scaffold biopsy was performed in 44 patients. The results were encouraging, revealing early tissue ingrowth by MRI, which was confirmed by histological evaluation that showed a good integration of the scaffold and the formation of meniscus-like tissue. Cartilage status proved to remain stable over time.

The same authors published clinical results at 2 years of follow-up in the same group of patients [29]. Statistically

relevant results were found in all clinical parameters examined and an overall better articular function and pain control were reported at final evaluation. Only one case required scaffold removal due to non-integration, although the patient was asymptomatic. Moreover, stable or improved cartilage status at imaging was reported in 92.5 % of patients treated.

Efe et al. [6] described the preliminary short-term results obtained in 10 patients treated with meniscal scaffold implantation and evaluated for up to 12 months of follow-up: there was a significant improvement in KOOS and Knee Society Score at 6 months evaluation, with a stable trend at 12 months of follow-up. Even MRI showed a gradual improvement in scaffold morphology and a preserved articular cartilage status.

Spencer et al. [23] reported their results after treating 23 patients with both CMI (12 patients) and polyurethane meniscus scaffold (11 cases). Overall clinical outcome at a mean of 19.1 months of follow-up was satisfactory for both treatment groups with comparable results.

The present study confirms these preliminary findings, showing good clinical and MRI results at 2 years of follow-up. No major adverse events were observed and an overall improvement in all scores was found, thus supporting the use of this scaffold for the treatment of partial meniscal lesions.

The limitations of the study are the lack of a control group, the short follow-up, the lack of cases evaluated through histological study, and the low number and heterogeneity of the patients treated. However, the high number of combined procedures is also useful, with respect to other more homogenous studies, to highlight that this scaffold can also be used in complex knee lesions where multiple comorbidities need to be properly addressed. Furthermore, the present pilot study highlighted the safety and potential of this polyurethane scaffold in promoting tissue restoration with good clinical and MRI results at the 2-year follow-up. Clinical relevance of the present study lies in the fact that it shows the feasibility of the application of this novel meniscal scaffold for treating both isolated partial meniscal loss and more complex knee lesions requiring concurrent procedures. In both cases, clinical outcome proved to be satisfactory, even if at short-term evaluation.

Further randomized studies with a larger number of patients and a longer follow-up time are needed to confirm these preliminary findings, compare the promising results obtained with those of the other available collagen-based scaffold, and determine whether the biomechanical properties of this polyurethane implant could really ensure better clinical results over time and alter the natural history of meniscus deficient knees otherwise doomed to early osteoarthritis degeneration.

Conclusions

In the present study, the safety and clinical efficacy of a novel polyurethane meniscal scaffold to treat partial meniscal loss have been reported. The 2-year follow-up of this pilot clinical study showed an improvement in all the parameters evaluated. Different trends in the clinical outcome were seen: patients who underwent combined surgery, such as cartilage treatment and osteotomy, presented a slower improvement, but achieved similar results after 2 years. Good results were also found with the MRI evaluation with regard to implant morphology, even if the signal was still hyper-intense in all scaffolds between 1 and 2 years of follow-up.

The clinical and MRI evaluations demonstrated good results, showing that this polyurethane meniscal scaffold may be safely and successfully applied in the treatment of partial meniscal loss.

Acknowledgments All the authors would like to thank Federica Balboni, Giulio Altadonna, Francesco Perdisa, Letizia Merli, Keith Smith, and Elettra Pignotti, all from the Rizzoli Orthopaedic Institute (Bologna, Italy) for their contribution in realizing this paper.

References

1. Aagaard H, Jorgensen U, Bojsen-Moller F (1999) Reduced degenerative articular cartilage changes after meniscal allograft transplantation in sheep. *Knee Surg Sports Traumatol Arthrosc* 7:184–191
2. Alhalki MM, Hull ML, Howell SM (2000) Contact mechanics of the medial tibial plateau after implantation of a medial meniscal allograft. A human cadaveric study. *Am J Sports Med* 28:370–376
3. Bulgheroni P, Murena L, Ratti C, Bulgheroni E, Ronga M, Cherubino P (2010) Follow-up of collagen meniscus implant patients: clinical, radiological, and magnetic resonance imaging results at 5 years. *Knee* 17(3):224–229
4. Cook JL (2005) The current status of treatment for large meniscal defects. *Clin Orthop Relat Res* 435:88–95
5. DeGroot JH (2005) Polyurethane scaffolds for meniscal tissue regeneration. *Med Device Technol* 16(7):18–20
6. Efe T, Getgood A, Schofer MD et al (2012) The safety and short-term efficacy of a novel polyurethane meniscal scaffold for the treatment of segmental medial meniscus deficiency. *Knee Surg Sports Traumatol Arthrosc* 20(9):1822–1830
7. Fairbank TJ (1948) Knee joint changes after meniscectomy. *J Bone Joint Surg Br* 30B:664–670
8. Genovese E, Angeretti MG, Ronga M et al (2007) Follow-up of collagen meniscus implants by MRI. *Radiol Med* 112(7):1036–1048
9. Gomoll AH, Filardo G, Almqvist FK et al (2012) Surgical treatment for early osteoarthritis. Part II: allografts and concurrent procedures. *Knee Surg Sports Traumatol Arthrosc* 20(3):468–486
10. Heijink A, Gomoll AH, Madry H et al (2012) Biomechanical considerations in the pathogenesis of osteoarthritis of the knee. *Knee Surg Sports Traumatol Arthrosc* 20(3):423–435
11. International Cartilage Repair Society. ICRS cartilage injury evaluation package. http://www.cartilage.org/_files/contentmanagement/ICRS_evaluation.pdf

12. Jones RS, Keene GC, Learmonth DJ, Bickerstaff D, Nawana NS, Costi JJ, Percy MJ (1996) Direct measurement of hoop strains in the intact and torn human medial meniscus. *Clin Biomech (Bristol, Avon)* 11(5):295–300
13. Klompmaker J, Veth RP, Jansen HW et al (1996) Meniscal repair by fibrocartilage in the dog: characterization of the repair tissue and the role of vascularity. *Biomaterials* 17(17):1685–1691
14. Klompmaker J, Veth RP, Jansen HW et al (1996) Meniscal replacement using a porous polymer prosthesis: a preliminary study in the dog. *Biomaterials* 17(12):1169–1175
15. Kon E, Filardo G, Tschon M et al (2012) Tissue engineering for total meniscal substitution. Animal study in sheep model: results at 12 months. *Tissue Eng Part A* 18(15–16):1573–1582
16. Lee SJ, Aadalen KJ, Malaviya P et al (2006) Tibiofemoral contact mechanics after serial medial meniscectomies in the human cadaveric knee. *Am J Sports Med* 34:1334–1344
17. Maher SA, Rodeo SA, Doty SB et al (2010) Evaluation of a porous polyurethane scaffold in a partial meniscal defect ovine model. *Arthroscopy* 26(11):1510–1519
18. Monllau JC, Gelber PE, Abat F et al (2011) Outcome after partial medial meniscus substitution with the collagen meniscal implant at a minimum of 10 years' follow-up. *Arthroscopy* 27(7):933–943
19. Paletta GA Jr, Manning T, Snell E, Parker R, Bergfeld J (1997) The effect of allograft meniscal replacement on intraarticular contact area and pressures in the human knee. A biomechanical study. *Am J Sports Med* 25:692–698
20. Pereira H, Frias AM, Oliveira JM, Espregueira-Mendes J, Reis RL (2011) Tissue engineering and regenerative medicine strategies in meniscus lesions. *Arthroscopy* 27(12):1706–1719
21. Rodkey WG, DeHaven KE et al (2008) Comparison of the collagen meniscus implant with partial meniscectomy. A prospective randomized trial. *J Bone Joint Surg Am* 90(7):1413–1426
22. Scotti C, Pozzi A, Mangiavini L et al (2009) Healing of meniscal tissue by cellular fibrin glue: an in vivo study. *Knee Surg Sports Traumatol Arthrosc* 17(6):645–651
23. Spencer SJ, Saithna A, Carmont MR, Dhillon MS, Thompson P, Spalding T (2012) Meniscal scaffolds: early experience and review of the literature. *Knee* 19(6):760–765
24. Steadman JR, Rodkey WG (2005) Tissue-engineered collagen meniscus implants: 5–6-year feasibility study results. *Arthroscopy* 21(5):515–525
25. Stone KR, Steadman JR, Rodkey WG, Li ST (1997) Regeneration of meniscal cartilage with use of a collagen scaffold. Analysis of preliminary data. *J Bone Joint Surg Am* 79(12):1770–1777
26. Szomor ZL, Martin TE, Bonar F, Murrell GA (2000) The protective effects of meniscal transplantation on cartilage. An experimental study in sheep. *J Bone Joint Surg Am* 82:80–88
27. Tienen TG, Heijkants RG, Buma P, De Groot JH, Pennings AJ, Veth RP (2003) A porous polymer scaffold for meniscal lesion repair—a study in dogs. *Biomaterials* 24(14):2541–2548
28. Tienen TG, Heijkants RG, de Groot JH et al (2006) Meniscal replacement in dogs. Tissue regeneration in two different materials with similar properties. *J Biomed Mater Res B Appl Biomater* 76(2):389–396
29. Verdonk P, Beaufils P, Bellemans J et al (2012) Successful treatment of painful irreparable partial meniscal defects with a polyurethane scaffold: two-year safety and clinical outcomes. *Am J Sports Med* 40(4):844–853
30. Verdonk R, Verdonk P, Huisse W et al (2011) Tissue in growth after implantation of a novel, biodegradable polyurethane scaffold for treatment of partial meniscal lesions. *Am J Sports Med* 39(4):774–782
31. Verdonk PC, Verstraete KL, Almqvist KF et al (2006) Meniscal allograft transplantation: long-term clinical results with radiological and magnetic resonance imaging correlations. *Knee Surg Sports Traumatol Arthrosc* 14(8):694–706
32. Verma NN, Kolb E, Cole BJ et al (2008) The effects of medial meniscal transplantation techniques on intra-articular contact pressures. *J Knee Surg* 21:20–26
33. Weinand C, Peretti GM, Adams SB et al (2006) An allogenic cell-based implant for meniscal lesions. *Am J Sports Med* 34(11):1779–1789
34. Wirth CJ, Peters G, Milachowski KA, Weismeier KG, Kohn D (2002) Long-term results of meniscal allograft transplantation. *Am J Sports Med* 30(2):174–181
35. Wyland DJ, Guilak F, Elliott DM, Setton LA, Vail TP (2002) Chondropathy after meniscal tear or partial meniscectomy in a canine model. *J Orthop Res* 20(5):996–1002
36. Zaffagnini S, Giordano G, Vascellari A et al (2007) Arthroscopic collagen meniscus implant results at 6–8 years follow up. *Knee Surg Sports Traumatol Arthrosc* 15(2):175–183
37. Zaffagnini S, Marcheggiani Muccioli GM, Grassi A et al (2011) Arthroscopic lateral collagen meniscus implant in a professional soccer player. *Knee Surg Sports Traumatol Arthrosc* 19(10):1740–1743
38. Zaffagnini S, Marcheggiani Muccioli GM, Lopomo N et al (2011) Prospective long-term outcomes of the medial collagen meniscus implant versus partial medial meniscectomy: a minimum 10-year follow-up study. *Am J Sports Med* 39(5):977–985